
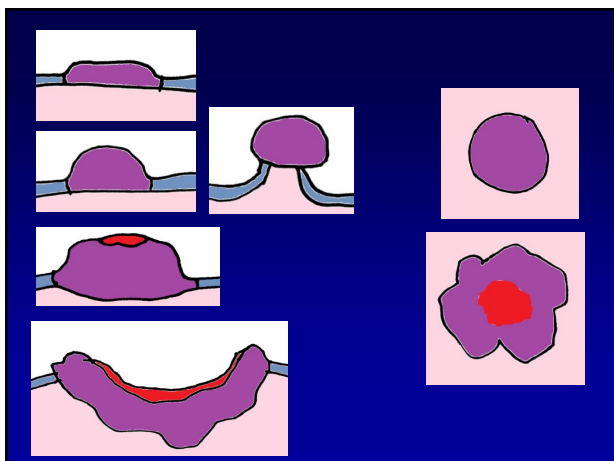
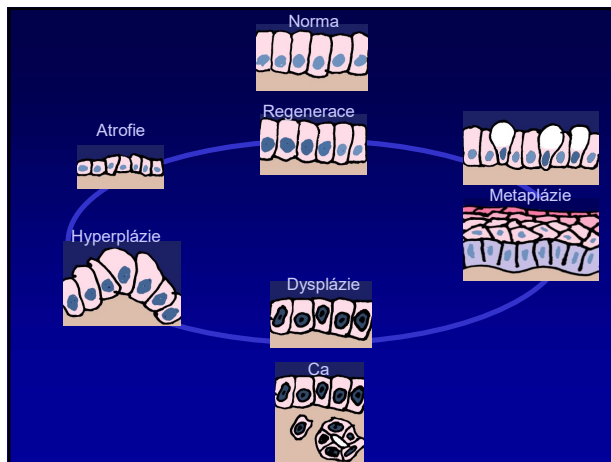
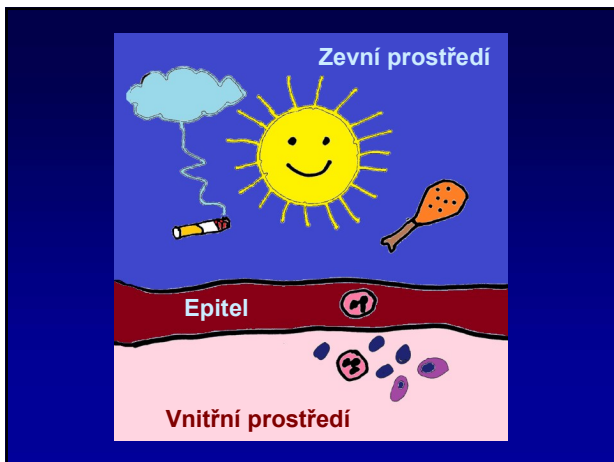
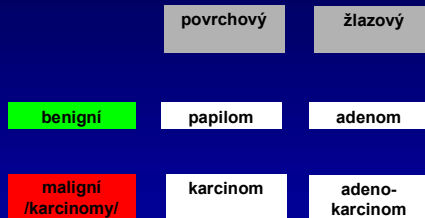


Klasifikace epiteliálních a neuroendokrinní nádorů

Vybraná schémata ze semináře

Jan Soukup
Patologie FNM

Epiteliální nádory




Šíření

Per continuitatem

(seróza => karcinóza)
(perineurální)

Lymfogenní

Hematogenní



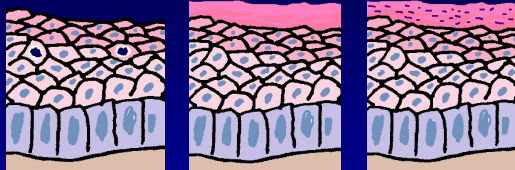papilomy



měkký x
fibroepiteliální



invertovaný



Koilocytóza

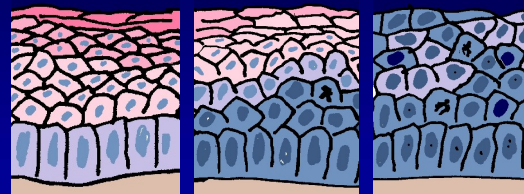
Hyperkeratóza

Parakeratóza

Dysplázie

LG


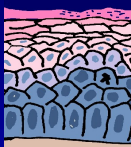
HG



1 - 2 - 3 - CIS



Sliznice
Leukoplakie



Kůže
Solární keratóza


Cornu cutaneum

Dlaždicobuněčný CA

Skvamocelulární ca
SCC

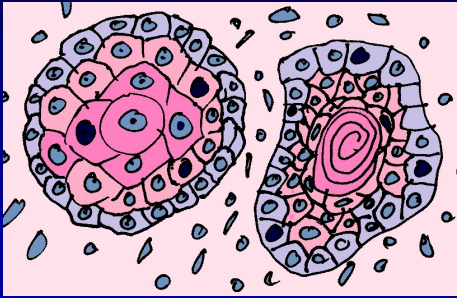
(spinocelulární ca
spinaliom
epidermoidní)

*dyskeratóza
keratinové perly*



SCC

diferenciace: vysoká /střední /nízká



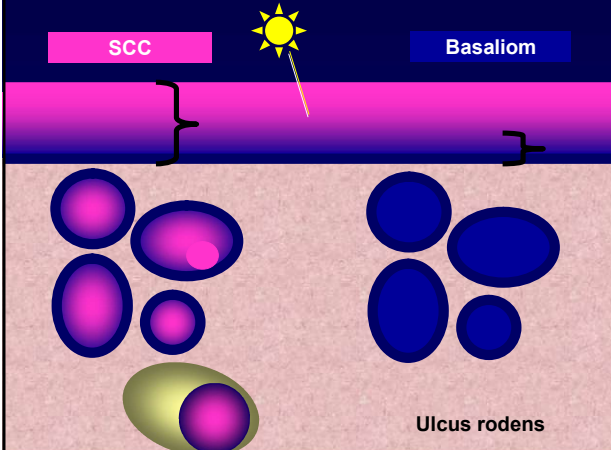
Verukózní karcinom




SCC

Basaliom

Ulcus rodens



Basaliom




uro

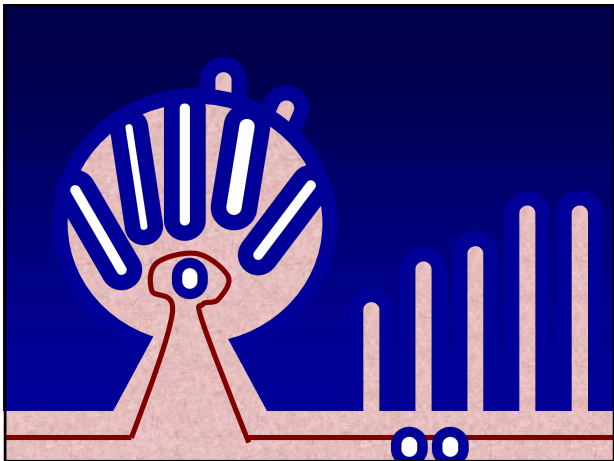
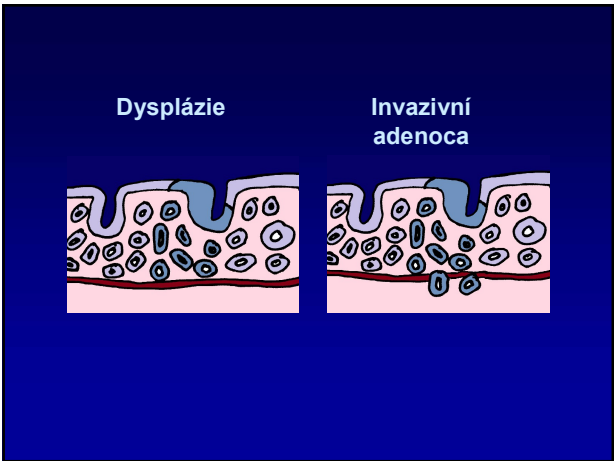
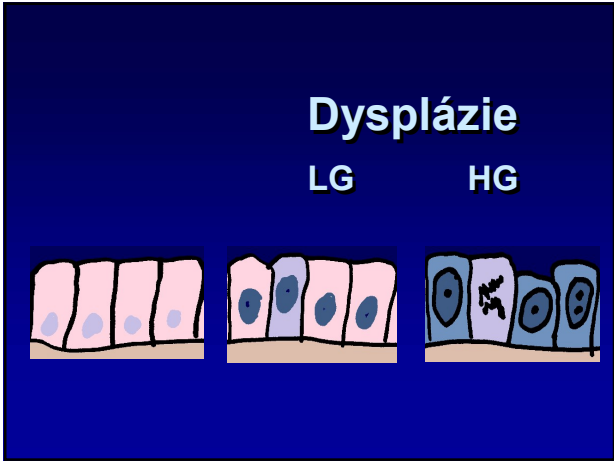
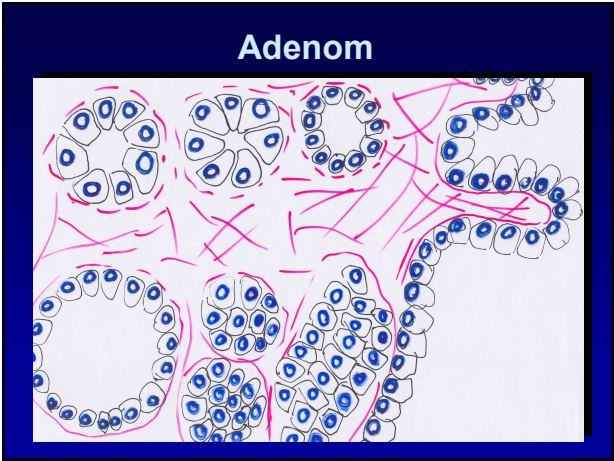
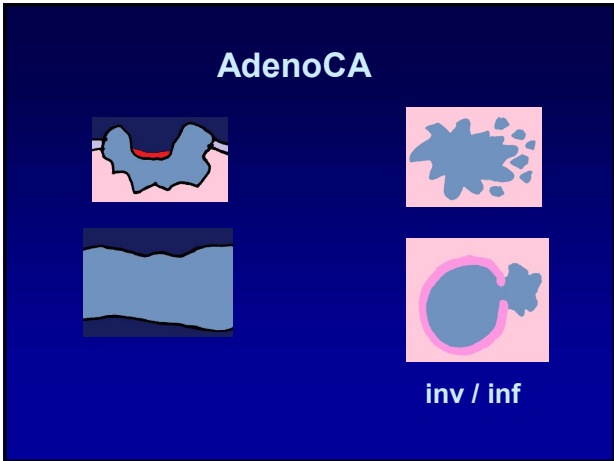
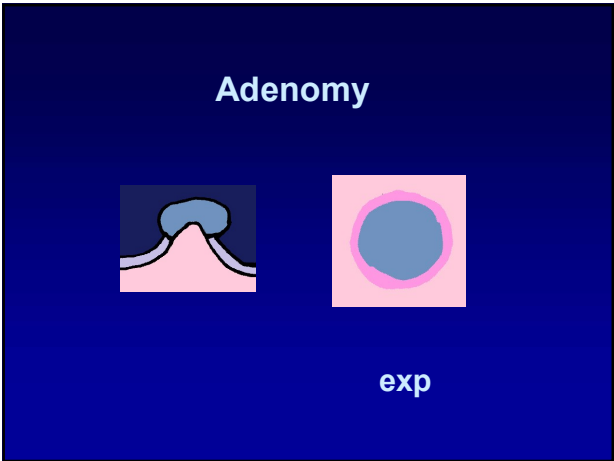
Papilom

Uroteliální karcinomy

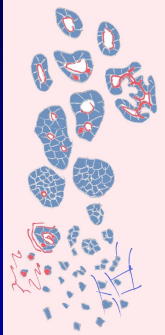
papilární neinvazivní

invazivní





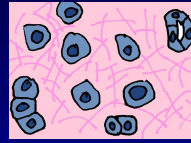
Adenokarcinom



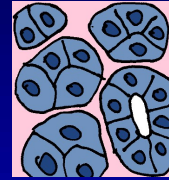
- tubulární
- kribrifonní
- solidní
- disociovaný

ADENOCA

skirhotický




medulární

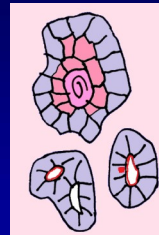


difúzní

Mucinózní adenoca



Smíšené

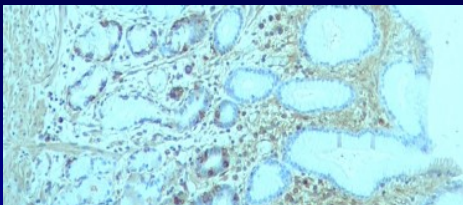


Adenoskvamozní
ca



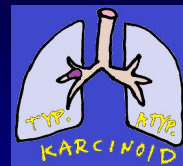Karcinosarkom

neuroendokrinní buňky:



Plíce: NEN = karcinoid + NEC

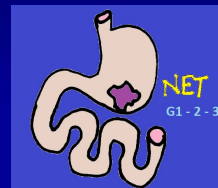
GIT: NEN = NET + NEC



Malobuněčný ca

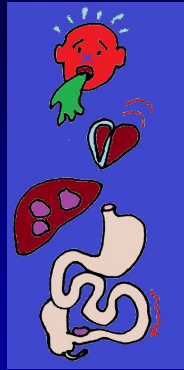
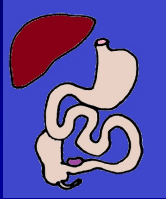


Velkobuněčný NEC

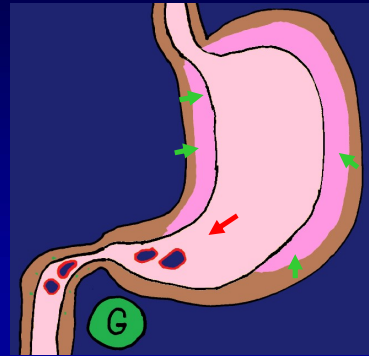


(MiNEN)

Karcinoidový sy
(serotonin apod.)



Zollinger-Ellison sy
(gastrinom)



KONEC