Pathology of pigments

MUDr. Jan Balko

Department of Pathology and Molecular Medicine,
2nd Faculty of Medicine, Charles University in Prague and
Motol University Hospital

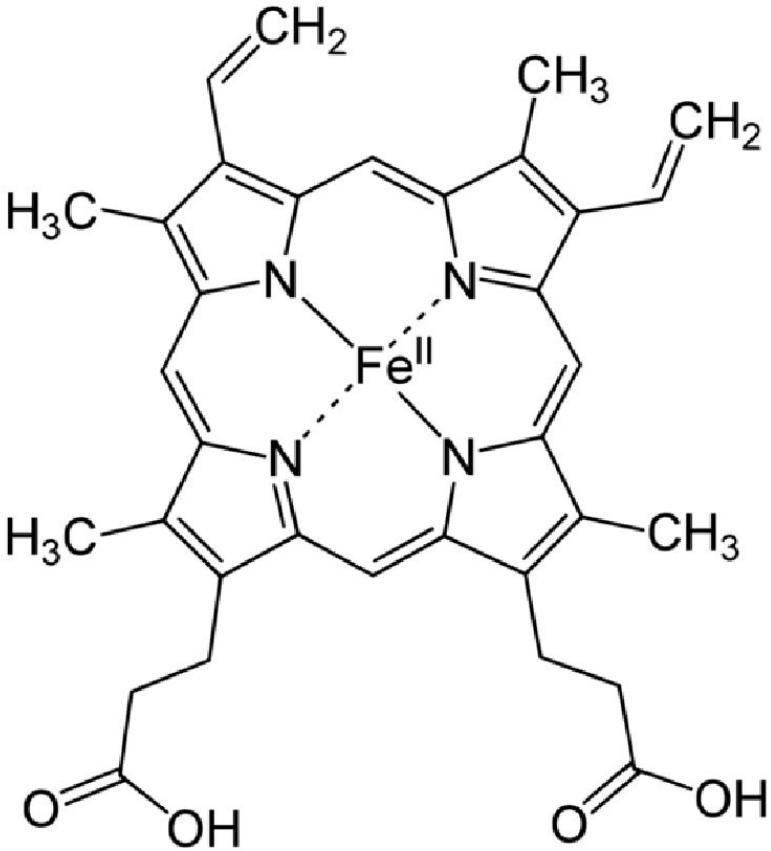

FN MOTOL

2. LF UK

Pigments

- **coloured** substances within the cell or in the extracellular matrix

(= intra- / extracellular; soluble / insoluble = corpuscular)

1) endogenous

2) exogenous

Pigments

1) endogenous

1) autogenous

- formed **by the cell** (metabolism product)

1) melanin
2) lipopigments

Pigments

1) endogenous

2) hematogenous

- formed by a **breakdown of hemoglobin**

1) hemosiderin
2) hematin
3) bilirubin + hematoidin
4) porphyrins

Pigments

2) exogenous

1) via traumatic lesions
2) via ingestion
3) via inhalation

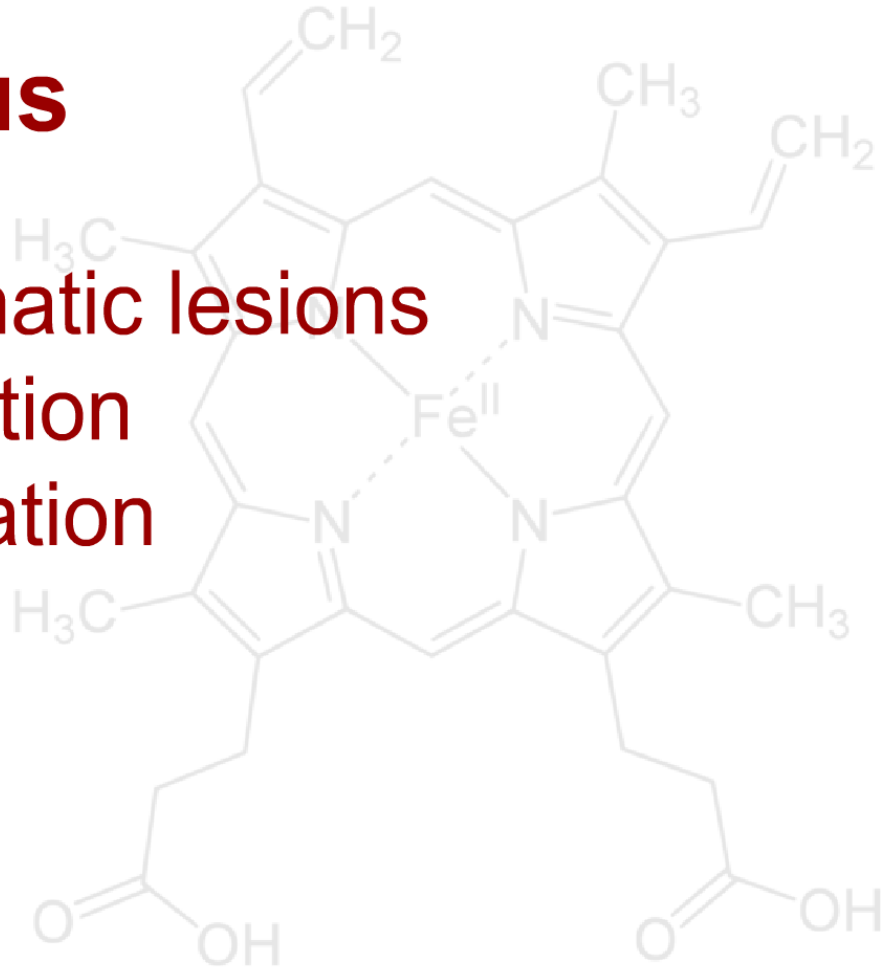

Endogenous (autogenous) pigments

Melanin

- **endogenous autogenous** pigment

Localization:

1) oculocutaneous

- origin in **melanocytes** of the skin (from tyrosine)
- skin, eye structures, menings, mucosal sites

1) **eumelanin**
2) **feomelanin**

Melanin

- **endogenous autogenous** pigment

Localization:

2) neuromelanin

- origin in the **neurones** (from dopamine)
- *substantia nigra, locus coeruleus*

Melanin

MICRO:

- granular, intracellular, **brown** to **black**
- destained with H_2O_2
- reducing $AgNO_3$ (Masson+ impregnation)
- PAS-, Fe-

IHC

- HMB45+, melan A+ (melanosomes, not melanin itself)

Melanin

Pathology:

1) hyperpigmentation

- **increase** of melanin

1) diffuse

2) focal

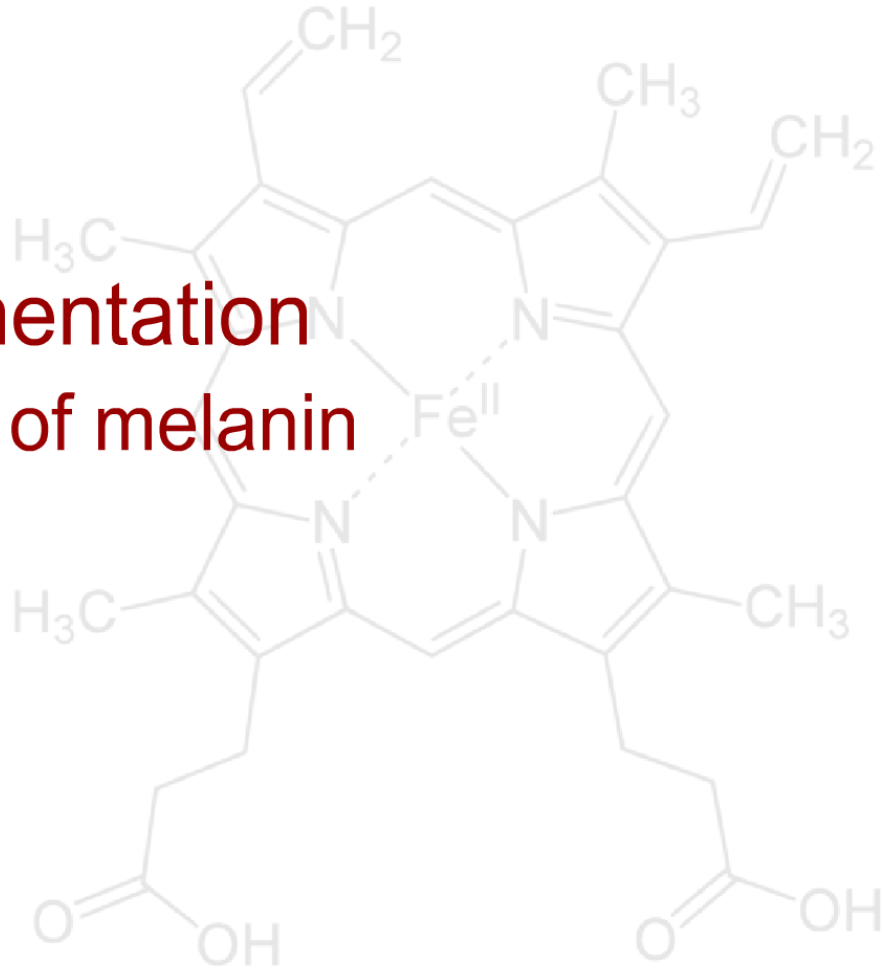

Melanin

Pathology:

2) hypopigmentation

- **lack** of melanin

1) diffuse

2) focal

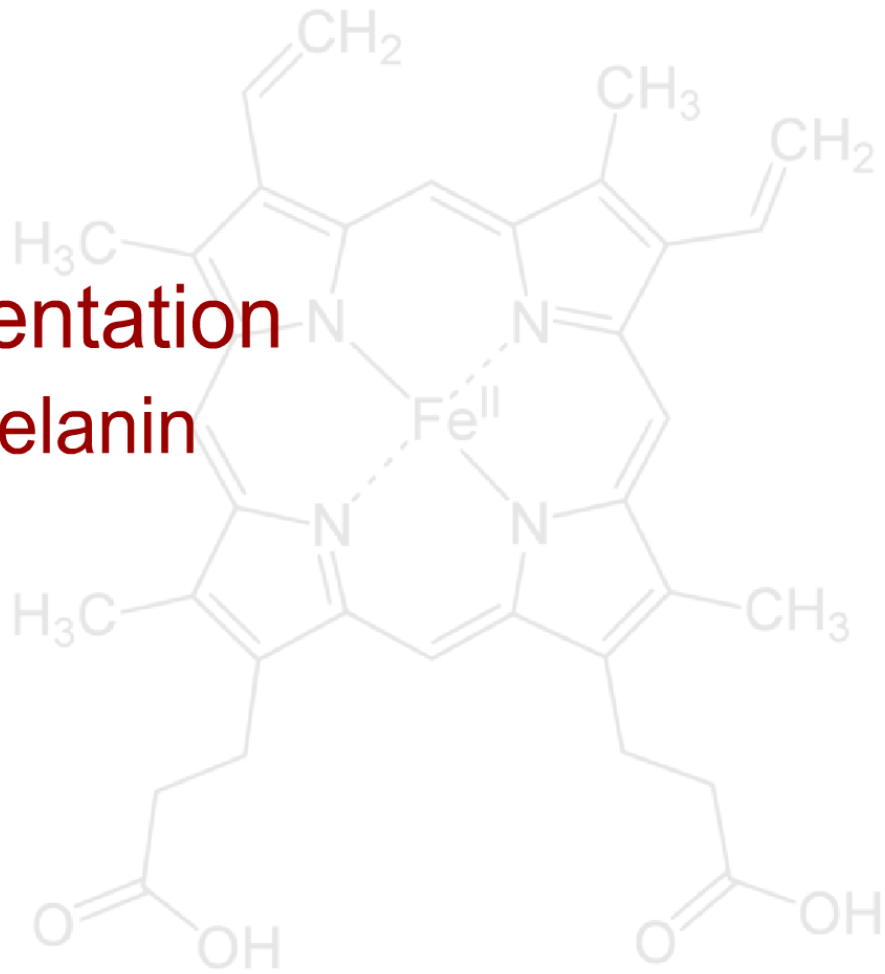

Melanin

1) hyperpigmentation

1) diffuse = **Addison's disease**

- *primary adrenocortical insufficiency*
- lack of mineralo- and glucocorticosteroids with reactive ↑ of ACTH + MSH (same precursor)

Melanin

1) hyperpigmentation

2) focal

1) **freckles** (*ephelides*)
2) **pigmented nevi** (*naevi pigmentosi*)
3) **melanodermia** (*chloasma*, *melasma*)
4) **melanoma**
5) **Peutz-Jeghers syndrome**

Melanin

1) hyperpigmentation

2) focal

1) **freckles** (*ephelides*)

- inherited formation of the skin spots
- after sunlight exposure (face, arms, shoulders)
- increased melanosomes, NOT melanocytes

Melanin

1) hyperpigmentation

2) focal

2) **pigmented nevi** (*naevi pigmentosi*)

- inherited formation of the skin spots
- hamartomas / benign tumours (anywhere)
- can be large, without effect of sun exposure
- increased melanocytes

Melanin

1) hyperpigmentation

2) focal

3) **melanodermia** (*chloasma*, *melasma*)

- acquired pigmented lesions of various origin
- influence of sunlight, hormones, cosmetics...

Melanin

1) hyperpigmentation

2) focal

4) **melanoma**

- malignant transformation of the meanocytes

Melanin

2) hypopigmentation

1) diffuse = **Albinism**

- autosomal recessive heredity
- tyrosinase deficiency
- oculocutaneous / ocular type

Melanin

2) hypopigmentation

2) focal

1) **vitiligo**

- acquired (but familial aggregation)
- idiopathic, but probably autoimmune origin
- white spots on the skin (face, genital area)
- total lack of melanocytes

Melanin

2) hypopigmentation

2) focal

2) **leucoderma**

- acquired
- postinflammatory origin (psoriasis, scars)
- doesn't have sharp border compared to vitiligo

Melanin-like pigments

- **endogenous autogenous** pigments similar to melanin:

1) Alkaptonuria

- rare AR deficiency of homogentisate 1,2-dioxygenase with alkapton accumulation in urine
- dark urine and risk of urolithiasis

Melanin-like pigments

- **endogenous autogenous** pigments similar to melanin:

2) Ochronosis

- alkapton accumulation in connective tissue
- **black** bones, cartilage and collagen
- ochronotic arthro- and spondylopathy

Melanin-like pigments

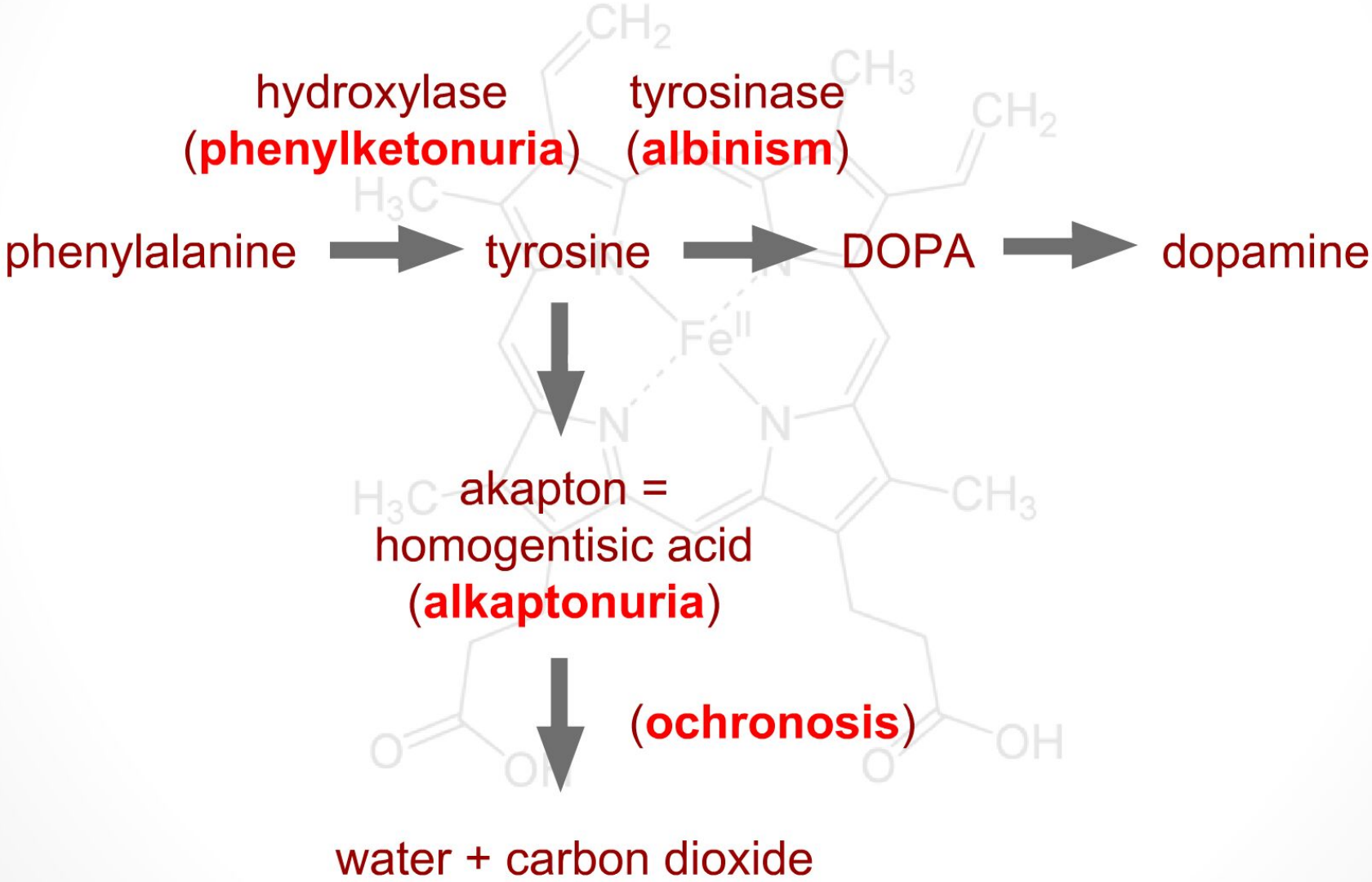

Lipopigments

- **endogenous autogenous** pigments

- lipids + proteins
  - intracellular (peroxidation of non-saturated lipid acids from membranes in autophagosomes)

Lipopigments

Localization:

1) Lipofuscin

- *"age-related lipopigment"*
- storaged within cells as they ages
- residual bodies in neurons, cardiomyocytes...
- **brown atrophy** (*atrophia fusca*) of organs

Lipopigments

Localization:

2) Ceroid

- *"disease-related lipopigment"* (similar to lipofuscin)
- storaged within cells during diseases
- result of **membranes destruction**
- haematoma, *melanosis coli*, avitaminosis E.,..

Lipopigments

MICRO:

- granular, corpusular, **yellow-brown**
- PAS+
- Masson-, Fe-

Autofluorescence

- **yellow**

Endogenous (hematogenous) pigments

Hematogenous pigments

- result of hemoglobin degradation (**hemolysis**):

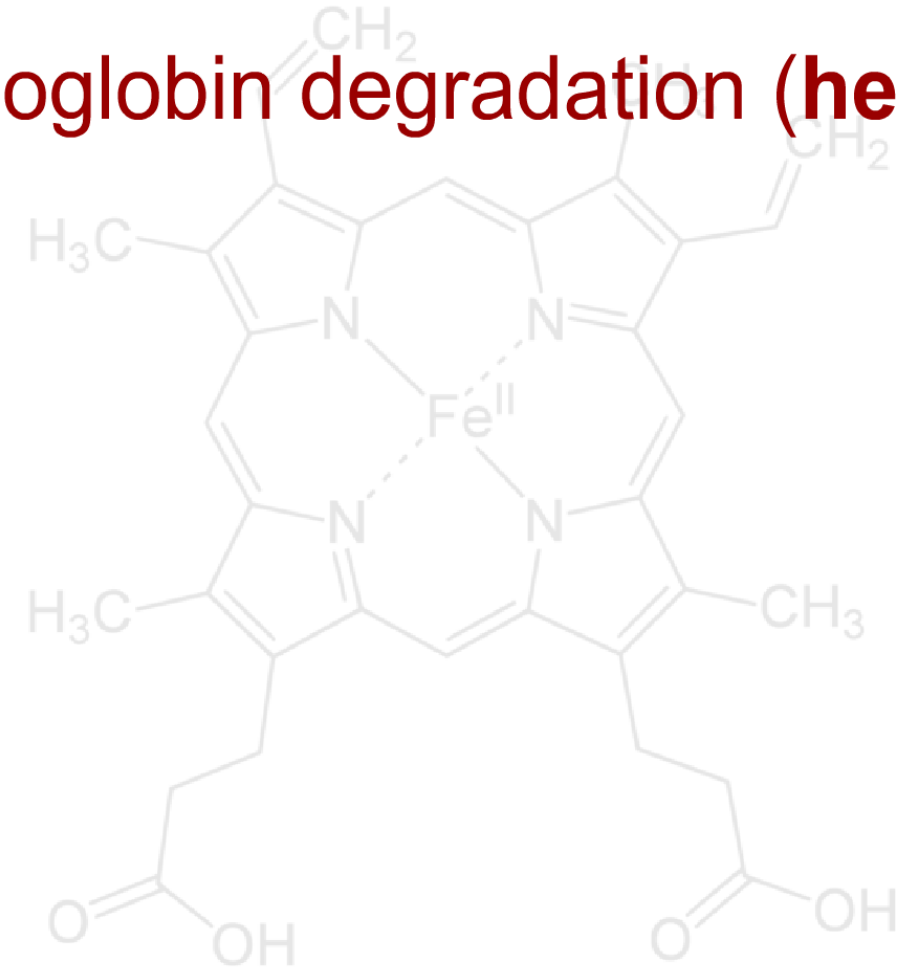

Hematogenous pigments

- hemolysis can be **extravascular**:
  - outside vessels
  - **normal** = RES
  - **pathology** = hematoma, hemorrhagic necrosis

Hematogenous pigments

- ...or **intravascular**:
  - inside vessels
  - **pathology** = hemolytic anemias

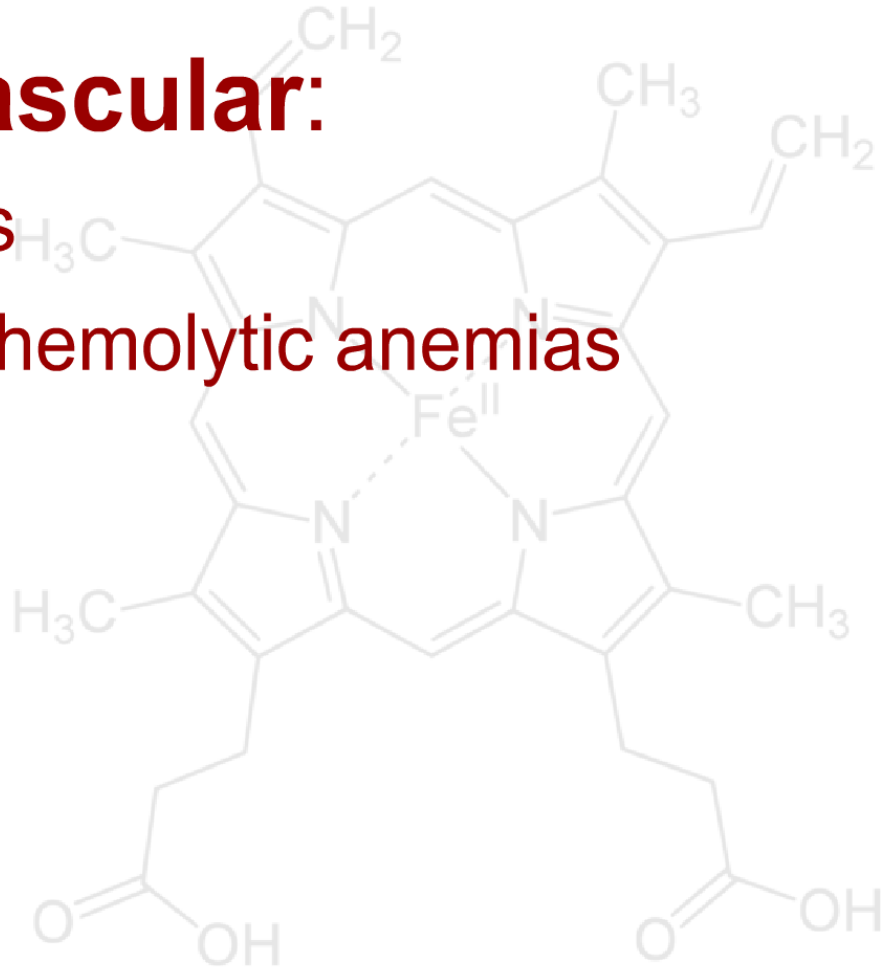

Hemosiderin

- **endogenous hematogenous** pigment

Localization:

- deposits of **Fe^{3+}** within tissues
  - result of aggregation and degradation of **ferritin** (within cell cytoplasm; Fe^{3+} + protein apoferritin)
  - present if there is an excess of iron (visible in LM)

Hemosiderin

MICRO:

- granular, **ferruginous**
- intra- (**siderophages**) / extracellular
- Fe+ Perls' reaction (Berlin = Prussian blue)
- PAS-, Masson-

Hemosiderin

Pathology:

1) localised hemosiderosis
2) diffuse hemosiderosis
3) hemochromatosis

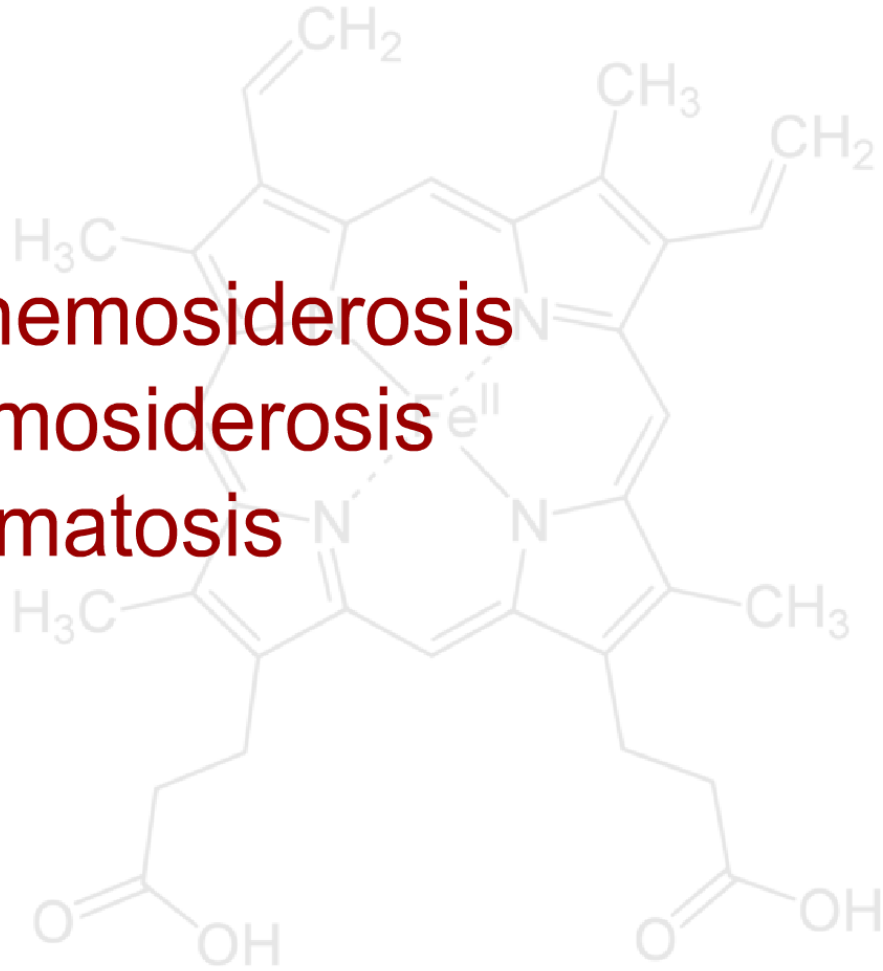

Hemosiderin

1) localised hemosiderosis

- foci of erythrocytes **extravasation**

- if **long-standing**, hemosiderin *damages DNA*
  + leads to *scar formation* (fibrotization)

- wall od hematoma, posthemorrhagic pseudocysts, brown induration of the lung

Hemosiderin

2) diffuse hemosiderosis ("secondary hemochromatosis")

- sign of chronic **hemolysis**

- mainly in RES (liver, BM, spleen), later heart, kidney, pancreas

- hemolytic anemias, repeated transfusion, iron overload

Hemosiderin

3) (primary / hereditary) hemochromatosis

- **inherited** defect of intestinal **absorption** of iron

- mutation of HFE gene (hepcidin expression = negative regulator of iron absorption)

- disrupts function of susceptible organs:

Hematin

- **endogenous hematogenous** pigment

Localization:

- obtained by the **oxidation** of heme
  - NOT present in healthy tissues
  - base of gastric ulcers, dry gangrene, malarial pigment, formalin artifacts

Hematin

MICRO:

- granular, **black**
- intra- / extracellular
- Fe-, PAS-, Masson-

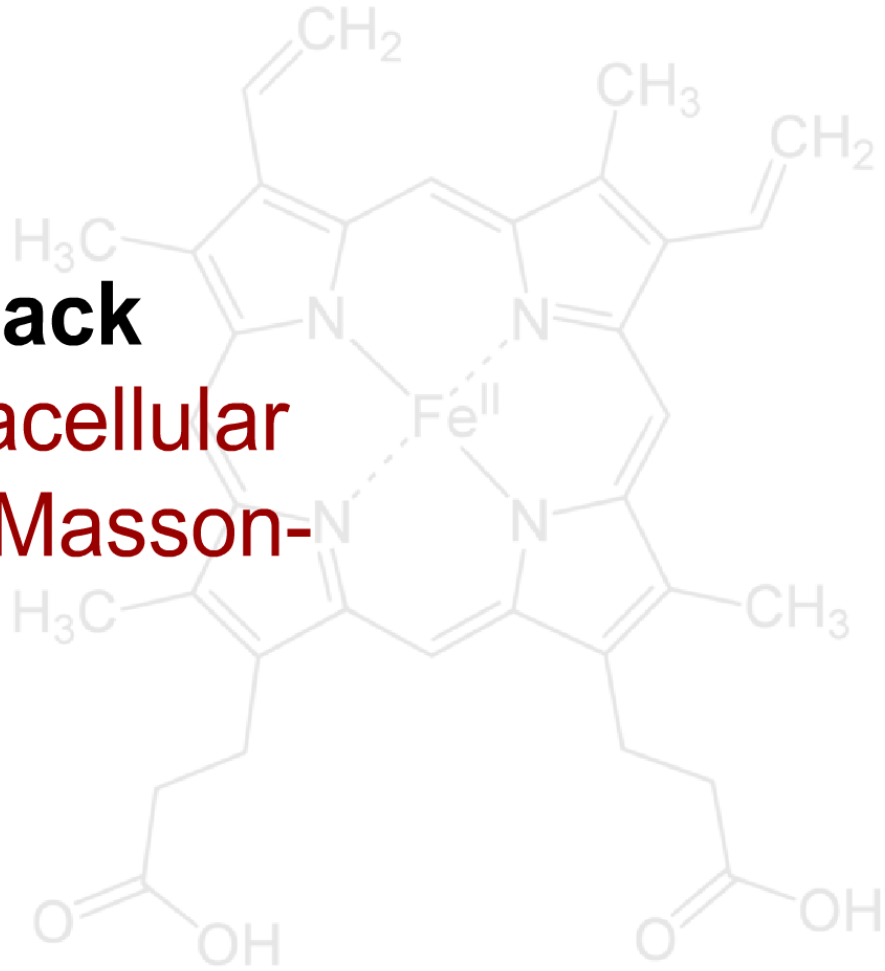

Hematoidin + Bilirubin

- **endogenous hematogenous** pigments

Localization:

1) Hematoidin

- **bilirubin** crystals at the periphery of hematoma

Hematoidin + Bilirubin

Localization:

2) Bilirubin

- bile pigment, result of **hemoglobin breakdown**
- intracellular (in **macrophages** of RES)

heme of Hb → biliverdin → non-conjugated bilirubin → transpor to liver (via albumin)

heme oxygenase (ER)

biliverdin reductase (cytosol)

Hematoidin + Bilirubin

MICRO:

1) Hematoidin

- crystals of rhombic shape, **yellow** to **red**
- extracellular (always)
- NOT containing Fe

Hematoidin + Bilirubin

MICRO:

2) Bilirubin

- invisible in light microscope
- **intracellular** (macrophages) / **in blood** (bound to albumin; nomally < 17 µmol/l)
- NOT containing Fe

Hematoidin + Bilirubin

Pathology:

Icterus (jaundice)

- **hyperbilirubinemia** > 30 µmol/l
- bilirubin leaves blood and inhabits tissues
- visible as **yellow** skin and conjunctiva (subicterus)
- symptom, NOT a disease

Hematoidin + Bilirubin

Pathology:

1) prehepatal (hemolytic) icterus

- ↑ bilirubin **production** (Hb breakdown)
- **laboratory** = ↑ non-conjugated bilirubin; ≈ ALT, AST
- hemolytic anemia, newborn jaudice (*i. neonatorum*), fetal erythroblastosis (*m. haemolyticus neonati*)
- severe causes brain damage ("Kernikterus")

Hematoidin + Bilirubin

Pathology:

2) hepatal (hepatocellular) icterus

- ↑ bilirubin caused by **hepatocyte damage**
- **laboratory** = ↑ both bilirubins; ↑ ALT, AST
- hepatitis, cirrhosis, toxic + ischemic hepatopathy

Hematoidin + Bilirubin

Pathology:

3) posthepatal (obstructive, cholestatic) icterus

- ↑ bilirubin because of **blockage of bile ducts** (intra- / extrahepatic)
- **laboratory =** ↑ conjugated bilirubin; ≈ ALT, AST; ↑ GGT + acholic stool (even steatorrhoea), dark urine, pruritus
- primary biliar cirrhosis, choledocholithiasis, drugs, strictures, tumours of bile ducts and panceras

Hematoidin + Bilirubin

Pathology:

4) inherited (familial) hyperbilirubinemia

- ↑ bilirubin because of **defective conjugation**
- Gilbert syndrome, Crigler-Najjar syndrome 1-2, Dubin Johnson syndrome, Rotor syndrome

Porphyrins

- **endogenous hematogenous** pigments

Localization:

- pigments contained in Hb, Mb and cytochrome
  - blood, muscles, liver

Porphyrins

MICRO:

- invisible in light microscope

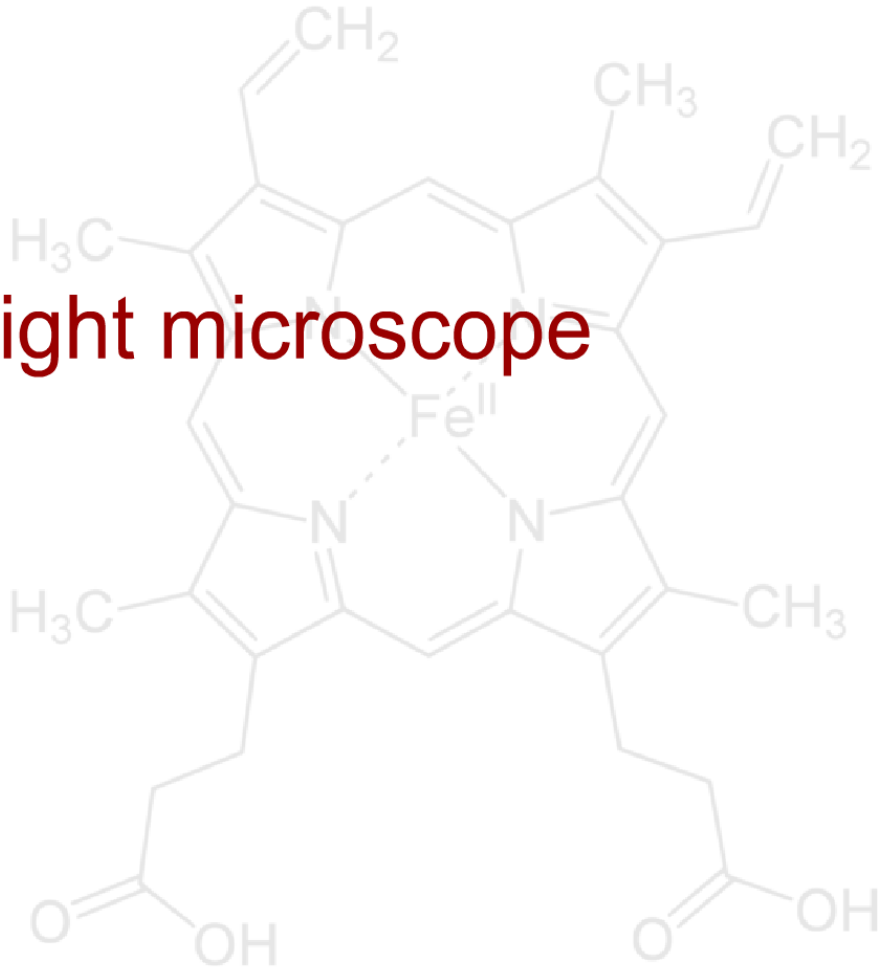

Porphyrins

Pathology:

- **inherited** = Porphyrias (defect in porphyrine metabolism = heme synthesis)
- **acquired** = mercury poisoning

Porphyrins

Pathology:

Porphyrias ("vampire disease")

- ↑ **production** of porphyrins (enzyme deficiency)
- several types of organ damage + acute / chronic
- **CNS + PNS toxicity** (pain, weakness, psychosis)
- **skin photosensitivity** (solar erythema, blisters, scar)
- **liver toxicity** (cirrhosis = *Porphyria cutanea tarda*)

Exogenous pigments

Pigments via traumatic lesions

Tautatio

1) arteficial (tattoo)

- mechanic instilation of **inert dyes** (china ink)
- **temporary** = into epidermis
- **permanent** = into dermis (macrophage degradation + transport into lymph nodes)

Pigments via traumatic lesions

Tautatio

2) traumatic

- mechanic instilation of **foreign bodies** into wound
- grit, sand, gunpowder, *siderosis cutis et bulbi*

Pigments via ingestion

- **GIT** absorption of several substances and distribution via blood (secondary colour change)

1) lipochrome (lutein)

- part of carotenoids (carrots)
- **yellow** fat tissue and blood serum in excess
- *xanthosis cutis* (skin in DM patients)

Pigments via ingestion

2) argyrosis

- chronic exposure to chem. forms of the element **silver**
- **greyish** skin
- drugs

3) chrysocyanosis

- chronic exposure to **gold** salts
- **bluish** skin
- drugs

Pigments via ingestion

4) mercury poisoning

- chronic exposure to **mercury**
- **greyish** rims on gingiva
- drugs

5) tetracycline

- exposure to **tetracycline ATB** in pregnancy / childhood
- **yellow** teeth of the baby / children

Pigments via inhalation

- **pneumoconioses** = see Lung pathology

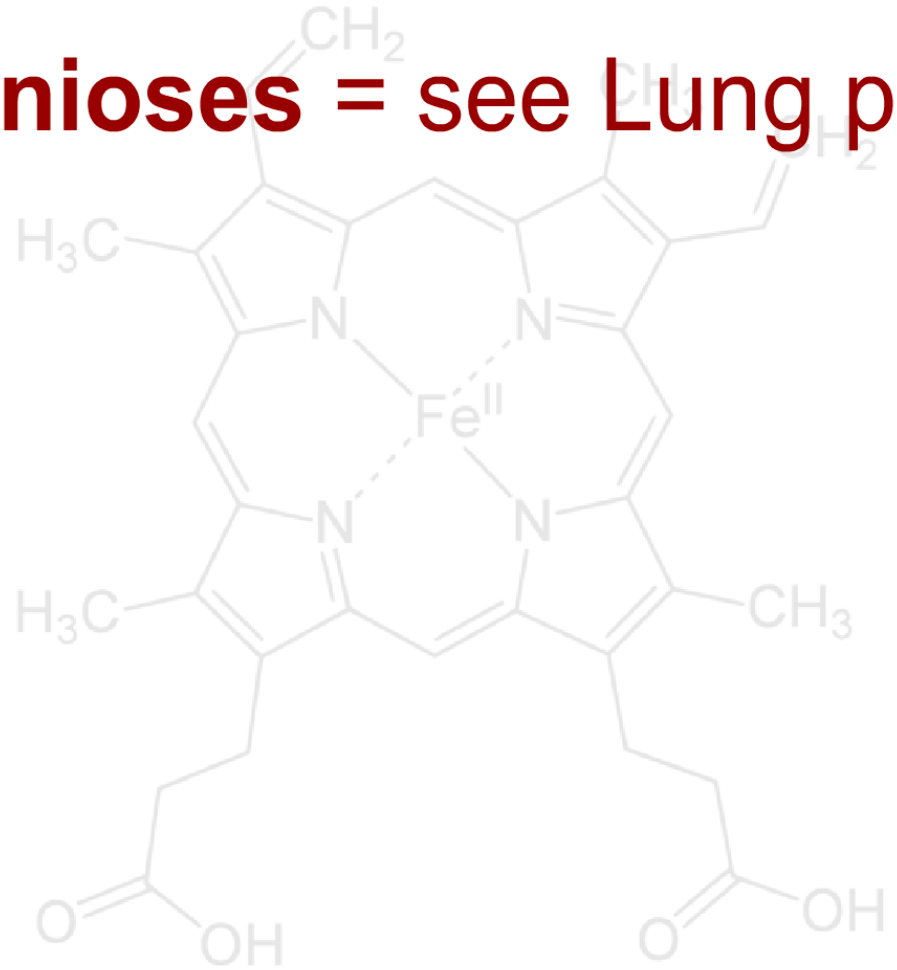

Literature:

- ZÁMEČNÍK, Josef. Patologie 1-3. 1. vydání, LD, s.r.o. - PRAGER PUBLISHING, 2019.

- STEJSKAL, Josef. Obecná patologie v poznámkách. 2. vydání. Nakladatelství Karolinum, 2005.

- POVÝŠIL, Ctibor; ŠTEINER, Ivo. Obecná patologie. 1. vydání. Nakladatelství Galén, 2011.

- BALKO, Jan; TONAR, Zbyněk; VARGA, Ivan. Memorix histologie. 1. vydání. Nakladatelství Triton, 2016.

- https://ucebnice-patologie.cz/