

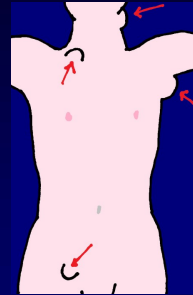
Pathology of the lymph nodes:

Reactive changes
/inflammation

Lymphadenopathy


- focal
- generalized
- conglomerate masses

- peripheral



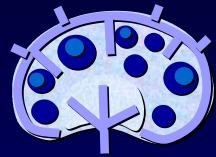Lymphadenopathy:

- Reactive changes
(inflamm, hyperplasia)
- Tumors
metastases
/lymphomas

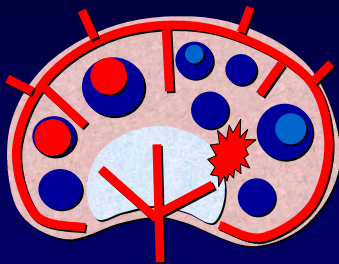


Lymphadenitis

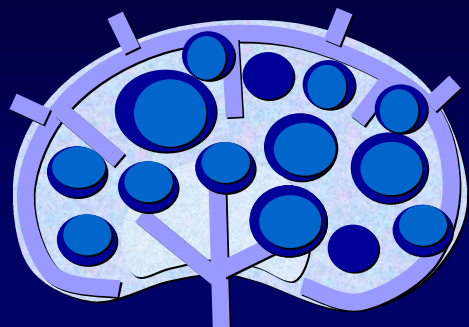
- Non-specific
 - Acute
 - Chronic
 - Hyperplastic
 - Follicular
 - Paracortical
 - Mixed
 - Atrophic
- Specific
 - Granulomatous
 - pure /necrotic /purulent

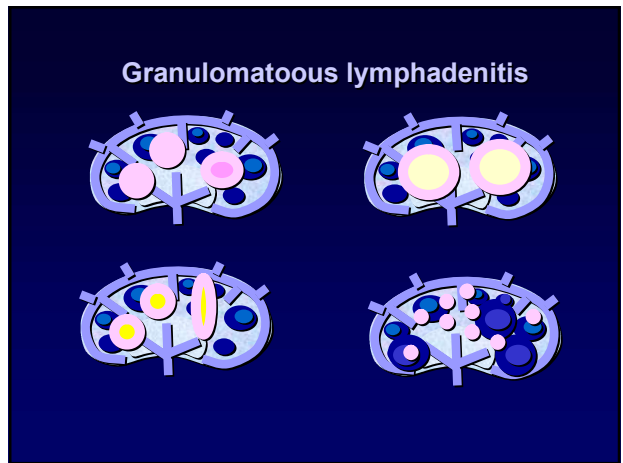
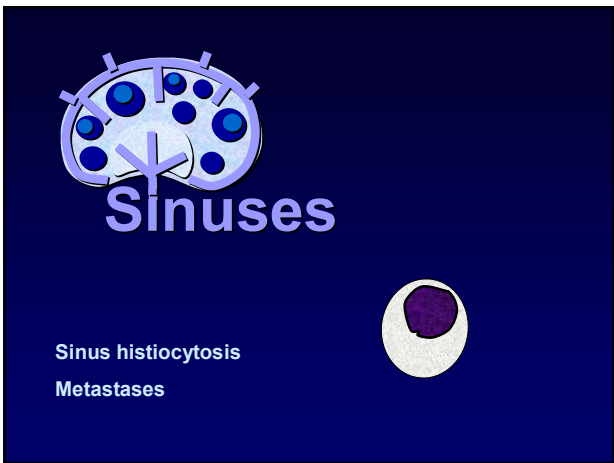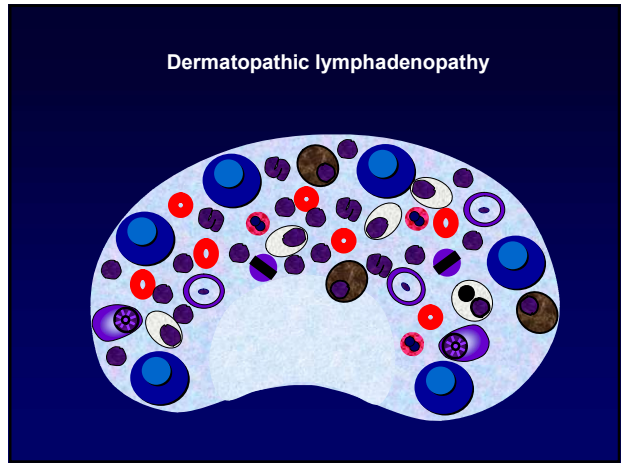
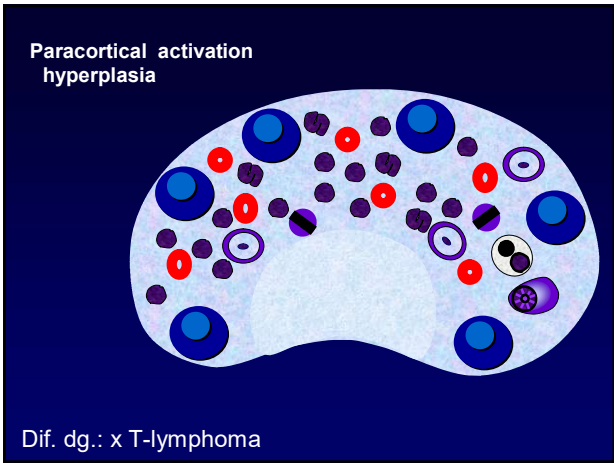
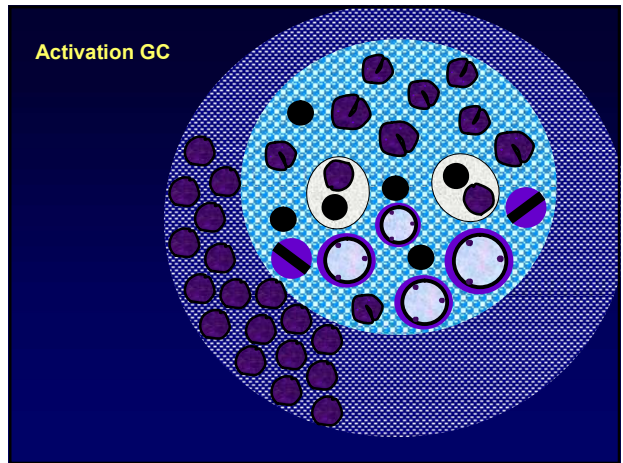
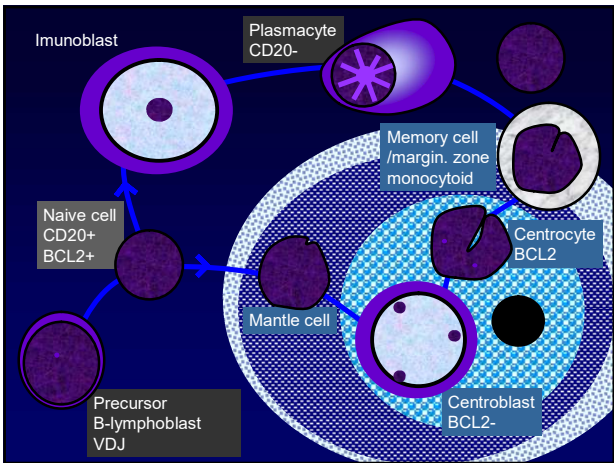


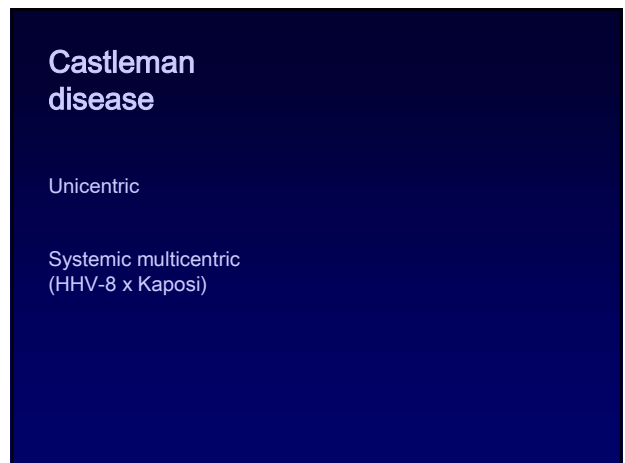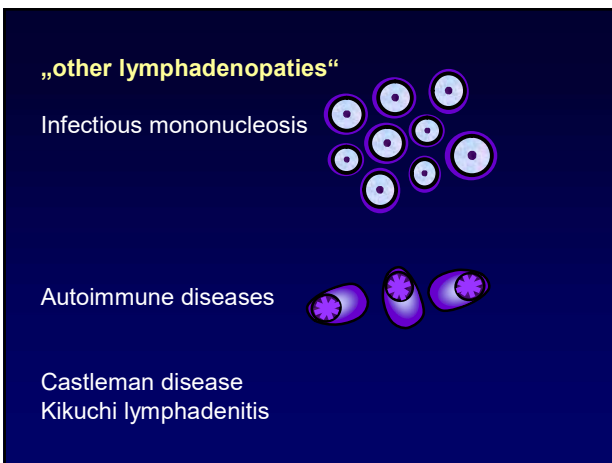
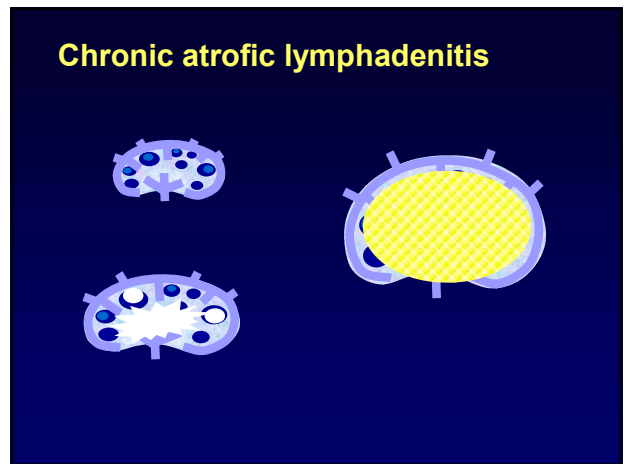
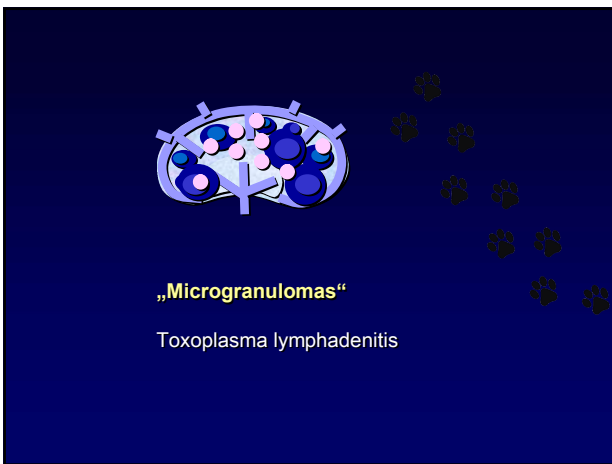
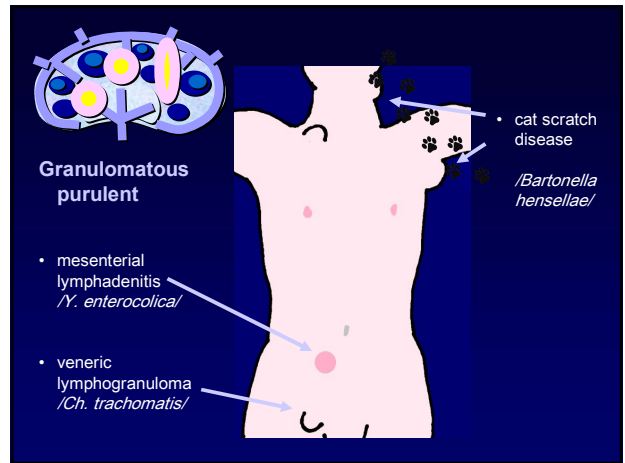
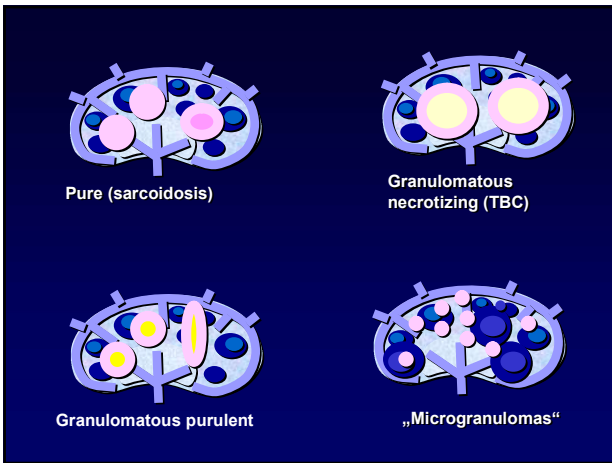
Acute non-specific lymphadenitis



Follicular hyperplasia







Kikuchi lymphadenitis

Necrotic process
Cervical lymph nodes
Young patients, females
(Japan)

Imunoblasts-macrophages-
apoptoses-necrosis
no neutrophils