



Arteries
 Degenerative diseases
 Atherosclerosis
 Aneurysmata
 Arteritis

Veins
 Phlebothrombosis
 (= embolism)
 Thrombophlebitis
 (pyaemia)
 Varices

Arteriosclerosis

- Atherosclerosis
- Mediocalcinosis
- Arteriolosclerosis

Mediocalcinosis

- lumen not narrowed
- calcification of muscularis
- Arteries of extremities

Arteriosclerosis

- Atherosclerosis
- Arteriolosclerosis

Arteriosclerosis

- Atherosclerosis
- Arteriolosclerosis

Arteriolosclerosis

- Older age
- hypertension
- DM: diabetic microangiopathy
(AGE Advanced Glycation end Products)

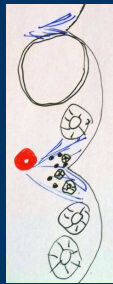arteriosclerotic nephrosclerosis:
hyaline x hyperplastic



kidney

Hyaline arteriolosclerosis

- endothelium: traumatization degeneration
- leakage of plasma
- perforated BM
- insudates in media
- (+ reaction of smooth muscle cells
→ increasing matrix)



arteriosclerotic
nephrosclerosis

Hyperplastic arteriolosclerosis

- malignant hypertension
- fibrinoid necrosis
- onion-like scarring

Atherosclerosis

Civilization disease:
Europe USA 50% deaths

Risk factors:
Endogenous
Acquired

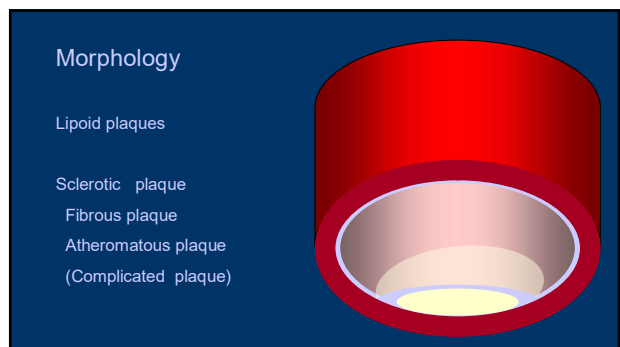
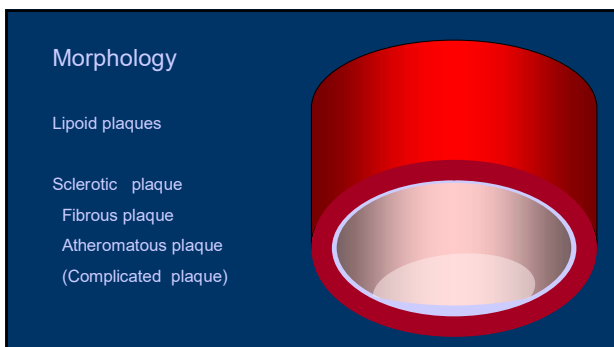
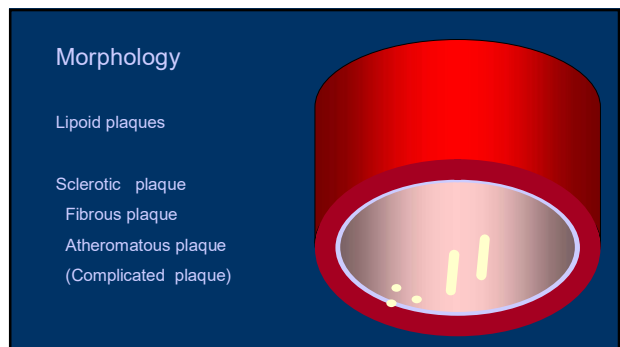

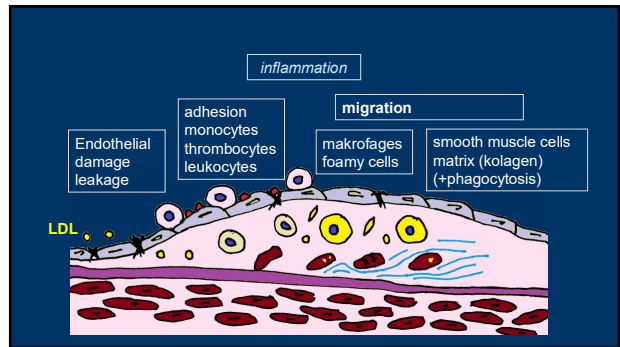
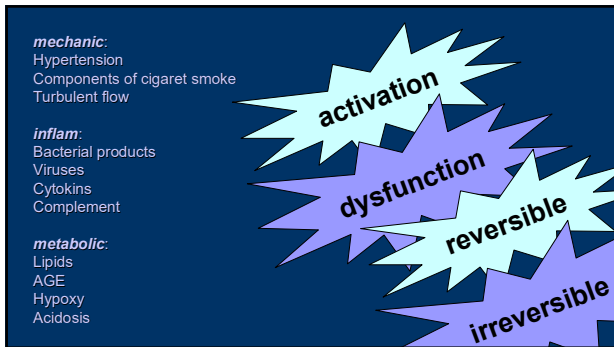


Endothelium

- Covering, barrier
- Production of extracellular matrix
- Blood clotting (antithrombotic x prothrombotic)
- Blood flow, vessel reaction (constriction x dilatation)
- Inflammation and immunity regulation
- Cell growth
- LDL oxidation

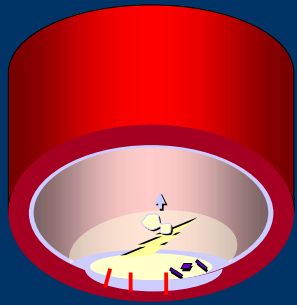
activation

dysfunction



Complications

- Calcifications
- Bleeding
- Ulceration
- Thrombosis




Complications

- Calcifications
- Bleeding
- Ulceration
- Thrombosis




Complications

- Calcifications
- Bleeding
- Ulceration
- Thrombosis



Acute



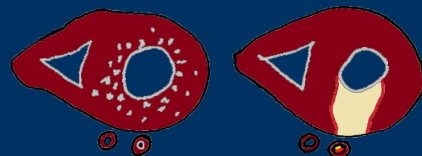
Chron

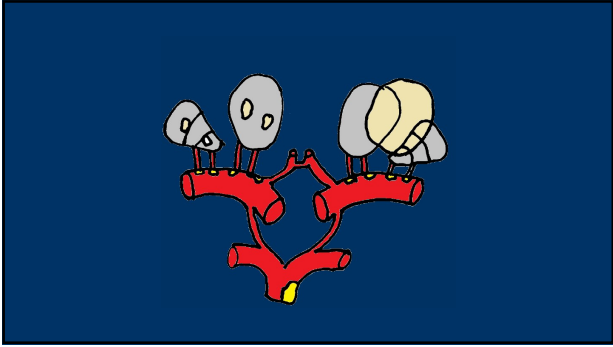
intestines
„claudications“
colitis
infarction



kidney
vascular atrophy
renal hypertension

lower extremities
claudications
gangrena






Atherosclerosis

Constitutional risk factors:

- Age
- Sex (M>F)
- Family disposition (familial hypercholesterolemia)

Acquired:


- Hyperlipidemia
- Hypertension
- Cigarettes
- DM
- Obesity
- Minimal physical activity
- Stress



multifunctional effects to atherosclerosis process
From initial changes up to complications

alcohol


- ↓ oxidative stress
- ↑ HDL
- ↑ efflux of cholesterol from vascular wall



Arterial aneurysmata


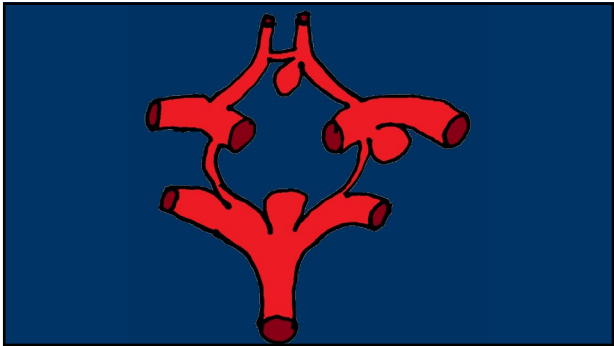
Vascular wall + lumen

Aorta (abdom)
Willis' circle
Polyarteritis nodosa

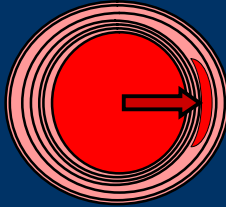


aneurysmata

- Saccatum
- Naviculare
- Diffusum
- Serpentinum
- Pseudo-A (Spurium)
- A-V

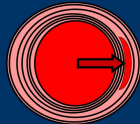



Dissecting aneurysma



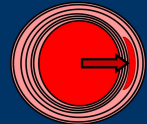
Dissection - etiology

- Unknown
- Variable (eg. malformation of aortic valve)
- hypertension
- degeneration of structure /extracellular matrix
- Senile
- Marfan's sy



Marfan's sy

- defect of fibrillin
- extracellular glykoprotein
- arachnodactylia, hyperextension of joints,
- dilatation of ostium aortae
- prolaps of mitral valve
- subluxation /dislocation of ocular lens



Vasculitis



- Uncommon but important
- Inflammatory symptoms
- Vascular occlusion – different organs
- Difficult dg.
- Clinician pathologist rheumatologist
- Agressive but curable

Vasculitis



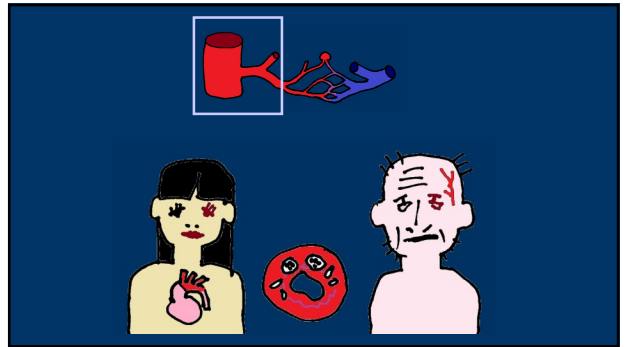
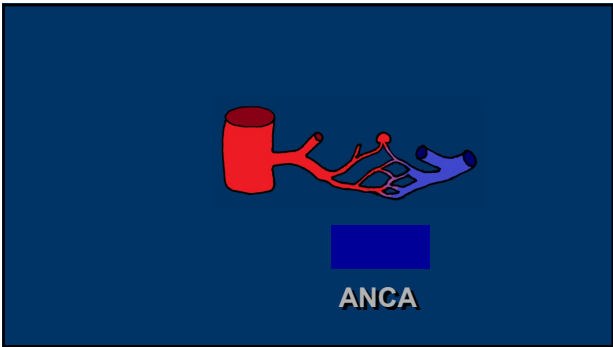
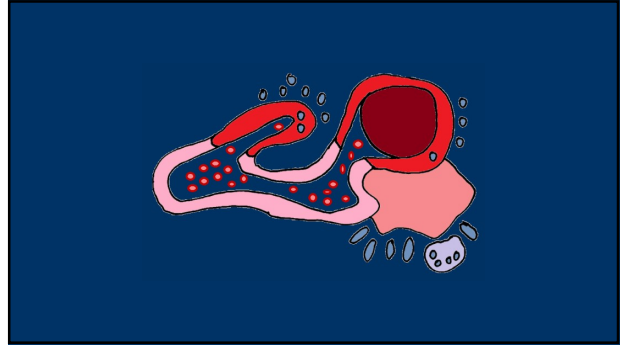
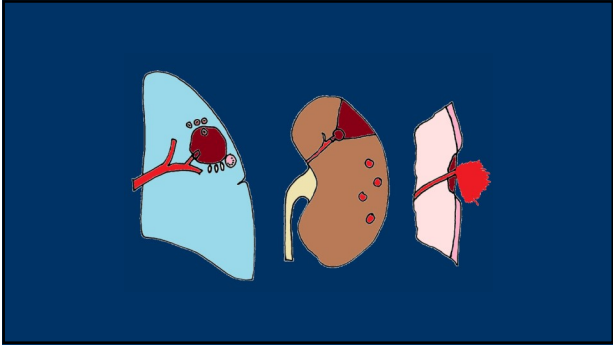
Infectious

(Neisseria, Spirochets, Mycotic)

sec



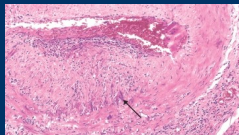

Noninfectious

prim



Giant cell temporal arteritis




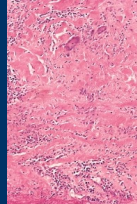
Age >50

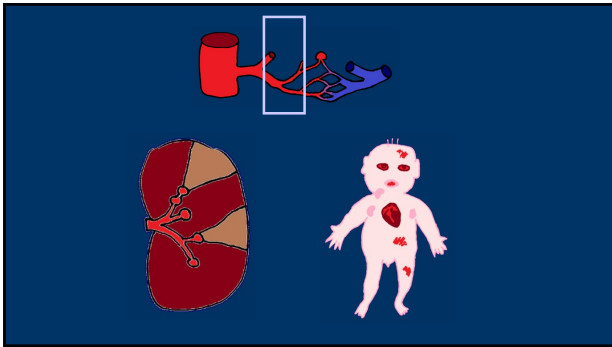





Takayasu arteritis
(pulseless disease)

Young females
Japan
Age <40
Idiopathic

segmental
giant cells
all layers



Polyarteritis nodosa

1/3 hepatitis B
immunocomplex
no lung
ANCA neg

Kawasaki disease
Mucocutaneous lymph node sy
Paediatric PAN

Etio?
Ab x
endothelium
infection?

Subsides spontaneously
Response to therapy

ANCA+

ANCA-

eosinophilic
granulomatosis
with polyangiitis
(sy Churg-
Strauss)

ANCA+

ANCA-

granulomatosis
with polyangiitis
(Wegener
granulomatosis)

microscopic
polyangiitis

ANCA+

ANCA-

IgA vasculitis
(Henoch-
Schönlein
purpura)

anti-GBM
glomerulonephritis
(Goodpasture sy)

Raynaud phenomenon

Young females

Cold/stress-induced paroxysmal
constriction of AA

Secondary (other:
SLE, compression)

Veins

- Phlebothrombosis
(=> embolism)
- Thrombophlebitis
(pyaemia)
- Varices

Phlebothrombosis:

Deep veins /legs

+ pelvic plexus

- oedema
 - embolism /thromboemb. disease
- Causes: venostasis, hypercoagulation,
gravity, contraceptives

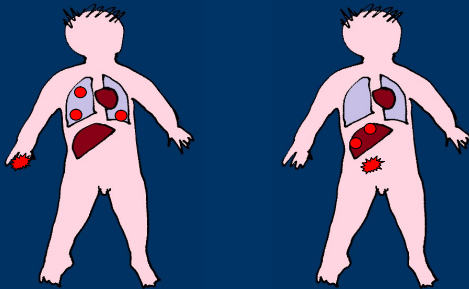
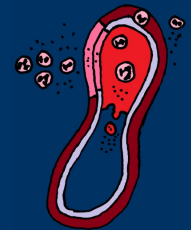Superficial (varicose veins)
palpable

Phlegmona

Thrombophlebitis

Pyaemia

Metastatic abscesses



Varicose veins

development:

legs, venous stasis

occupational – standing, drivers

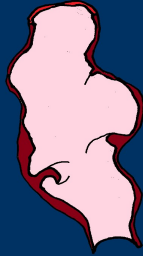pregnancy, obesity

inherited disposition

Varicose veins

Morphology:

Dilatation
Elongation
Tortuosity
Atrophy
Scarring
Calcifications
Hyperplasia
Valve deformation
Thrombosis



Varicose veins

Complications:

Thrombosis (~~Embolism~~)

Leg: Oedema

Stasis dermatitis

Atrophy, haemosiderin, trophic defects, ↓ regeneration, varicose ulcers, CA

Varicose veins - other localisations:

Hemorrhoids – gravidity, obstipations, cirrhosis

Oesophageal varices - cirrhosis