

ZÁNĚT / INFLAMMATION

non-living causes



reparation

living agents / causes



defence ... reparation

microorganisms and inflammation



sustain
multiply
spread

X



eliminate
supress
localize



repair



scar
formation



regeneration



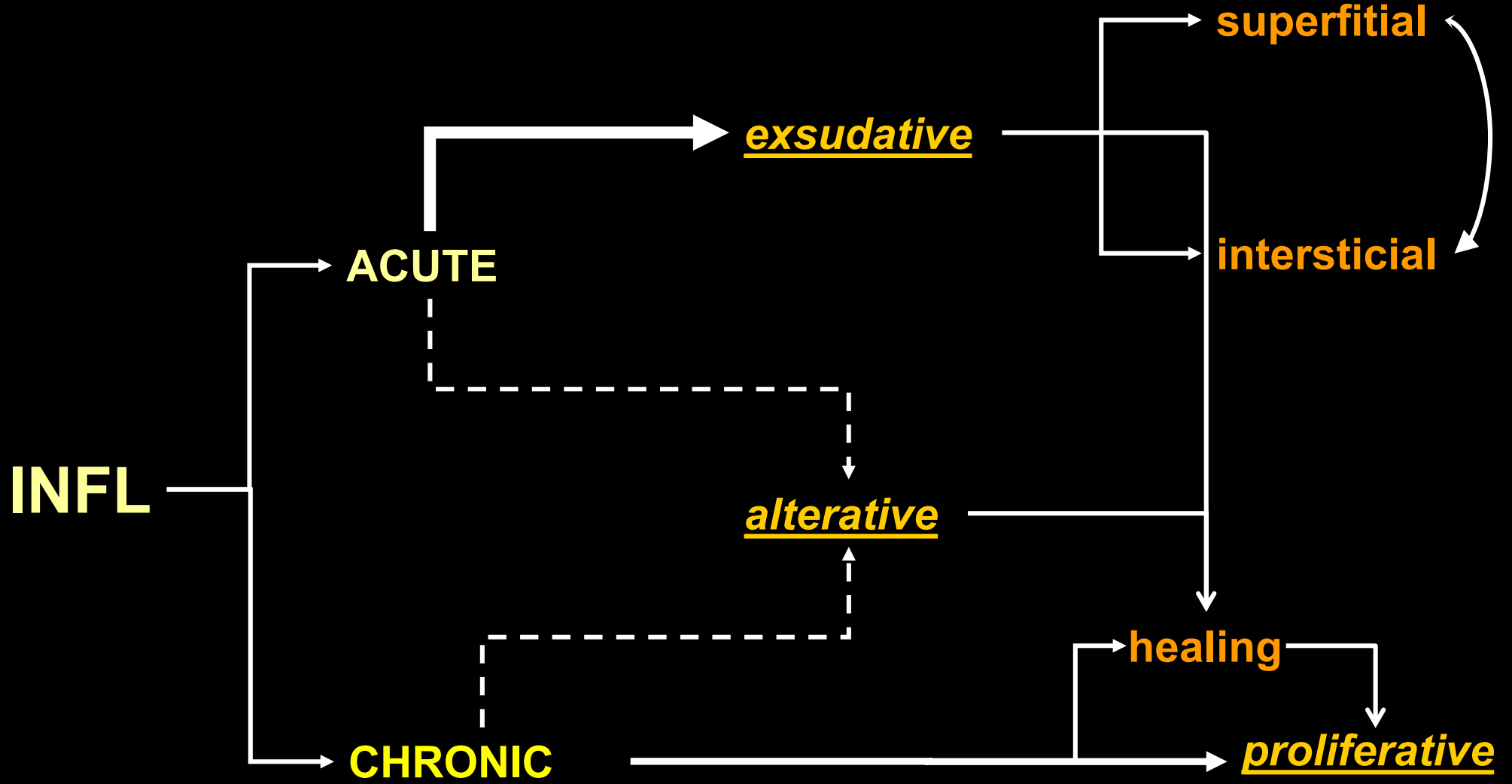
exaggerated
reaction

INFLAMMATION

exsudative

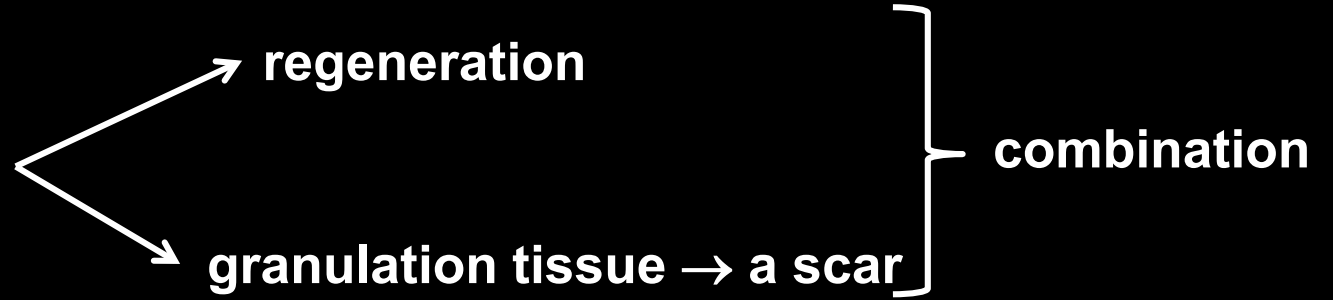
alterative

proliferative

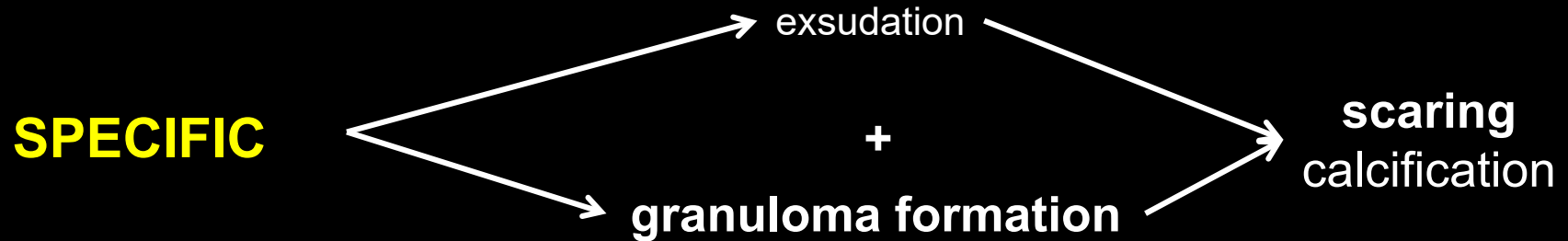
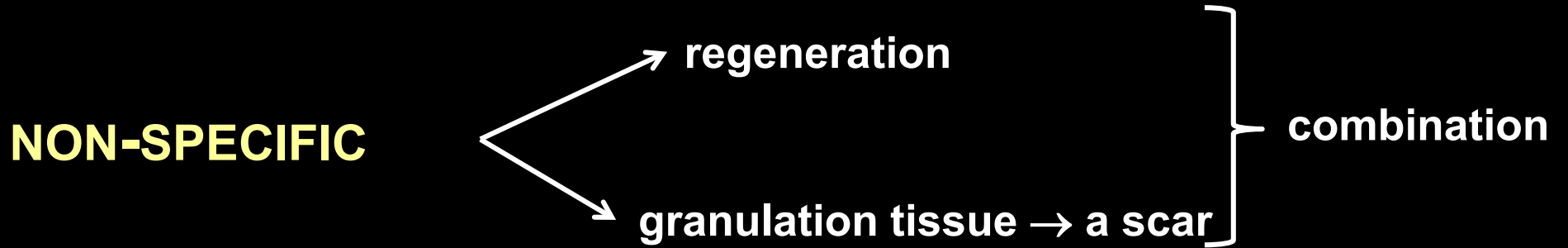


INFLAMMATION

NON-SPECIFIC



INFLAMMATION



no regeneration

INFLAM. acute and its development

- regeneration (resolution at integrum)
- healing through granulation tissue → scar formation
- progression → eg. colliquation → abscess ...
- transition to a chronic state

INFLAM. chronic primary

- persistent cause (infections, stones)
- exposition to insoluble materials (silica)
- autoimmune mechanisms

INFLAM. – main action of IL-1 and TNF

bacterial products, immune complexes, toxins, damage, other cytokines



activation of macrophages and other cells



IL-1 / TNF



reaction of acute phase

fever

+ sleaping

- loss of appetite

+ proteins of acute phase

neutrophils

hemodynamic effects (shock)

INFLAM. – main action of IL-1 and TNF

bacterial products, immune complexes, toxins, damage, other cytokines



activation of macrophages and other cells



IL-1 / TNF



reaction of acute phase reactants
fever
+ sleeping
- loss of appetite
+ proteins of acute phase reactants
neutrophils
hemodynamic effects (shock)

role of endothelia
+ adhesion of leucocytes
+ synthesis of PGI₂
+ procoagulative activity
- anticoagulative substances
+ IL-1, IL-8, IL-6, PDGF

INFLAM. – main action of IL-1 and TNF

bacterial products, immune complexes, toxins, damage, other cytokines



activation of macrophages and other cells



IL-1 / TNF



reaction of acute phase reactants
fever
+ sleeping
- loss of appetite
+ proteins of acute phase reactants
neutrophils
hemodynamic effects (shock)

role of endothelia
+ adhesion of leucocytes
+ synthesis of PGI₂
+ procoagulative activity
- anticoagulative substances
+ IL-1, IL-8, IL-6, PDGF

role of fibroblasts
+ proliferation
+ synthesis of collagen
+ PGE synthesis

INFLAM. – main action of IL-1 and TNF

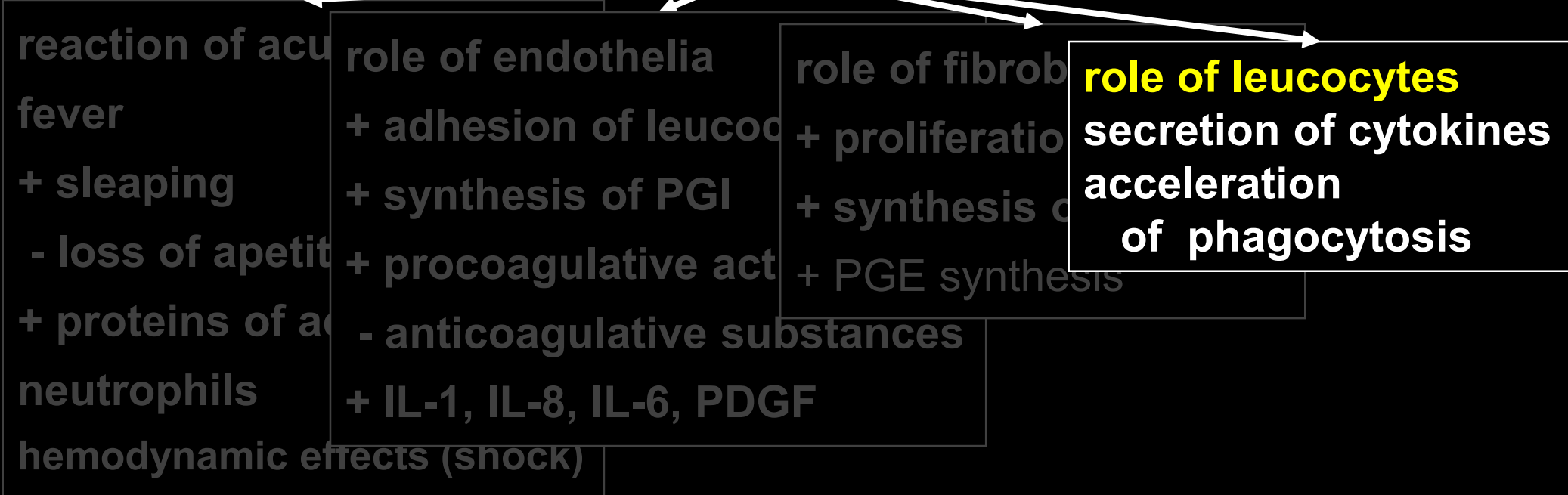
bacterial products, immune complexes, toxins, damage, other cytokines



activation of macrophages and other cells



IL-1 / TNF



ACUTE INFLAMMATION

1. vascular changes – exsudation of fluid

év

2. cell participation – migration of leukocytes

ACUTE INFLAMMATION

1. vascular changes – exsudation of fluid

a) dilatation and increase blood flow

b) increased vascular permeability

2. cell participation – migration of leukocytes

ACUTE INFLAMMATION

1. vaskulární změny – exsudace tekutiny

a) v průsvitu a průtoku krve cévami

b) ve zvýšení permeability cév

- kontrakce endoteliálních buněk
- přímé poškození endotelií <
- poškození endotelu leukocyty
- zvýšená transcytóza
- únik tekutin z regenerujících cév

ZÁNĚT AKUTNÍ

1. vaskulární změny – exsudace tekutiny

a) v průsvitu a průtoku krve cévami

b) ve zvýšení permeability cév

- kontrakce endoteliálních buněk
- přímé poškození endotelií <
- poškození endotelu leukocyty
- zvýšená transcytóza
- únik tekutin z regenerujících cév

2. buněčná účast - migrace leukocytů

ZÁNĚT AKUTNÍ

1. vaskulární změny


a) v průsvitu a průtoku krve cévami

b) ve zvýšení permeability cév

- kontrakce endoteliálních buněk
- přímé poškození endotelií <
- poškození leukocyty
- únik tekutin z regenerujících cév

2. buněčná účast - migrace leukocytů

- marginace, pavimentace, adheze
- emigrace
- fagocytosa a degranulace



VALENÍ

3

AKTIVACE

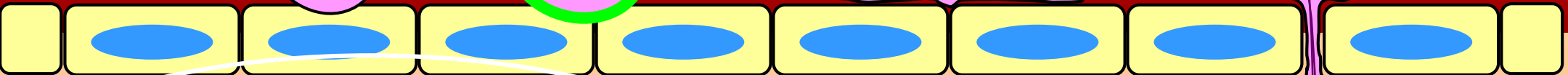




4

ADHEZE

5

TRANSMIGRACE

6



AKTIVACE

TNF
IL-1

chemoatraktanty


STIMULUS

2

1

CHEMOTAXE

7



**macrophages -
phagocytosis**

opsonization

Fc IgG

C3bi

collectins

3 steps:

recognition and adhesion

engulfment

killing and degradation

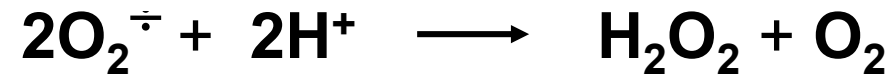
C1q



**metabolic
activation
of macrophages**


**macrophages -
phagocytosis**

NADPH oxidase



regurgitation

**macrophages -
phagocytosis**



neutrophils

fagolysosome + azurophilic granules

MPO +

**Cl^- converts H_2O_2
to HClO**

chloric acid - antimicrobial

**katalase $\text{H}_2\text{O} + \text{O}_2$
glutathion oxidase**

**degradation of
dead bodies by hydrolytic enzymes**

BPI

bakterial permeability increasing protein

lysozyme

lactoferrin

MBP

eosinofils

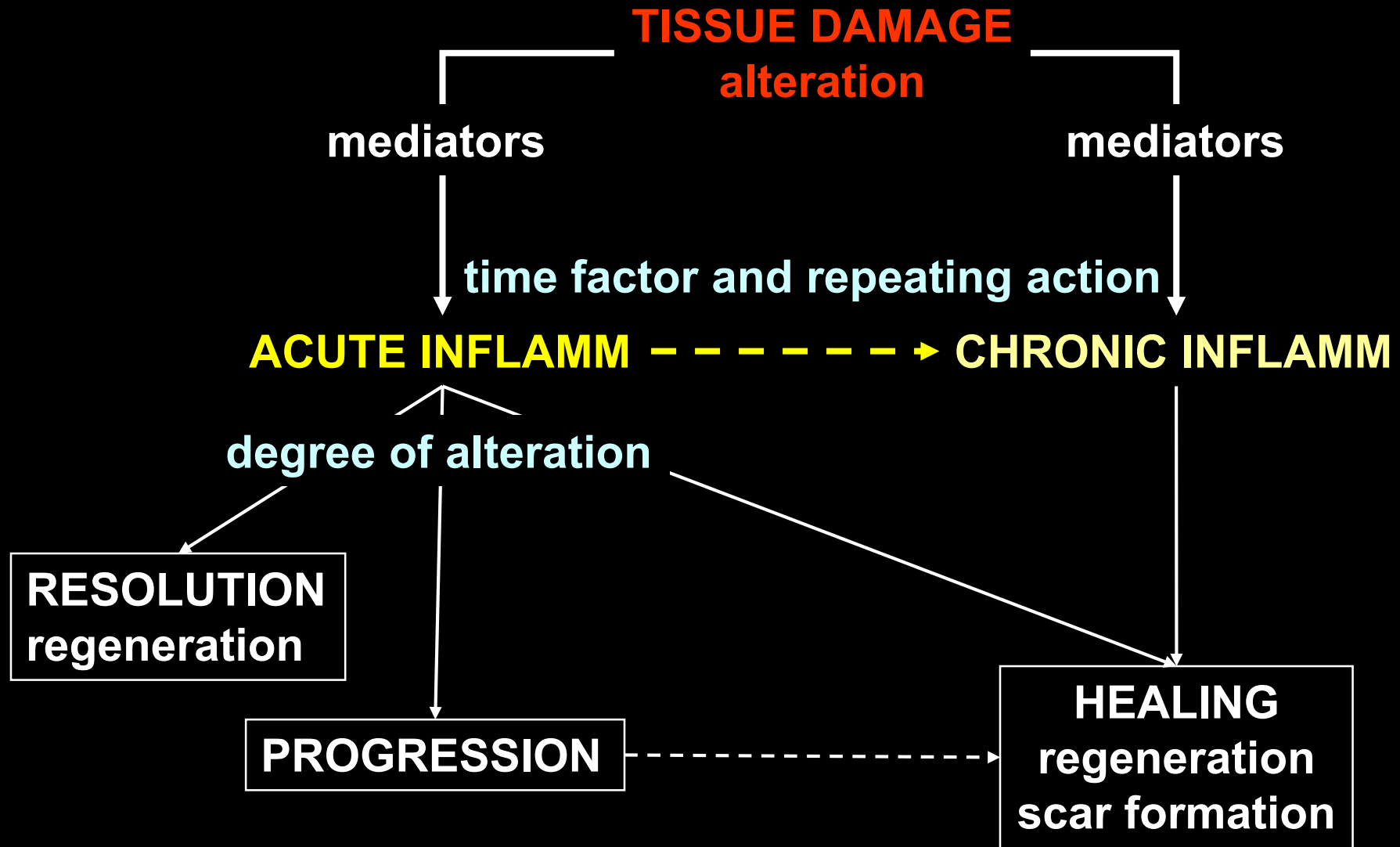
defensines

fibrin organization

granulation tissue


scar formation - fibroproduction

Results of acute inflammation



Morphology and classification of non-specific inflammation


type	tissue	examples
serous	serous surfaces skin	
lymphocytic	mucosa interstitium	
fibrinous		
purulent		
gangrenous		



degree of damage = alteration → healing

Morphology and classification of non-specific inflammation


type	tissue	examples
serous	serous surfaces skin	
lymphocytic	mucosa interstitium	
fibrinous		
purulent		
gangrenous		



degree of damage = alteration → healing

Morphology and classification of non-specific inflammation

type	tissue	examples
serous	serous surfaces	
lymphocytic	skin	
fibrinous	mucosa	
	interstitium	
purulent		
gangrenous		



degree of damage = alteration → healing

**fibrinous
interstitial**

Rheumatic fever


β -hemolytic streptococcus – *faryngitis, tonsillitis*

- 1. polyarthritis - migrating**
 - 2. carditis**
 - 3. rheumatic nodules - subcutaneous**
 - 4. erythema marginatum – skin**
 - 5. chorea minor Sydenhami**
- = Jones major criteria**

- 1. fever**
 - 2. arthralgy**
 - 3. laboratory signs of acute infection (ASLO, CRP)**
- = Jones minor criteria**

Morphology and classification of non-specific inflammation

type	tissue	examples
serous	serous surfaces	
lymphocytic	skin	
	mucosa	
	interstitium	
fibrinous		
purulent		
gangrenous		



degree of damage = alteration → healing

**purulent interstitial
abscess formation**


**purulent interstitial
abscess formation**

pyogenic membrane

**purulent interstitial
phlegmone**

Morphology and classification of non-specific inflammation

type	tissue	examples
serous	serous surfaces skin	
lymphocytic	mucosa interstitium	
fibrinous		
purulent		
gangrenous		



degree of damage = alteration → healing

wet gangrene

Morphology and classification of non-specific inflammation

chronic inflammation

reparative phase with long term healing

primary chronic

autoimmune

CHRONIC INFLAMMAION
persisting stimuli

activated macrophages and lymphocytes

growth factors
(PDGF, FGF, TGF β)

cytokines
(TNF, IL-1, IL-4, IL-13)

decreased activity of
metaloproteinases

proliferation:
fibroblasts
endotelia

increased synthesis
of collagens

decreased degradation
of collagens

FIBROSIS

**chronic inflammation
fibroproductive**